

# Successful application of thrombolysis and angioplasty in case of mechanical aortic valve and coronary graft thrombosis

Ieva Norkienė<sup>1</sup>,

Ieva Kažukauskienė<sup>2</sup>,

Robertas Samalavičius<sup>3</sup>,

Kęstutis Ručinskas<sup>4</sup>

<sup>1</sup> Clinic of Anaesthesiology  
and Intensive Care,  
Faculty of Medicine,  
Vilnius University,  
Vilnius, Lithuania

<sup>2</sup> Center of Cardiology,  
Vilnius University Hospital  
Santariškių Clinics

<sup>3</sup> Vilnius University Hospital  
Santariškių Clinics

<sup>4</sup> Clinic of Cardiovascular Diseases,  
Faculty of Medicine,  
Vilnius University

Prosthetic valve thrombosis (PVT) is a rare and fatal complication requiring immediate treatment. Optimal management of the left-sided obstructive PVT is still controversial and depends on patient's status, estimated risk of surgery, thrombus location and size, and clinician's experience. We report a case of a 71-year-old woman, presenting with signs of cardiogenic shock. Transesophageal echoscopy was used to diagnose acute obstructive thrombosis of the mechanical aortic valve. Concomitant coronary graft thrombosis was suspected due to signs of acute myocardial infarction. Thrombolysis with alteplase and subsequent stenting of the venous graft lead to successful resolution of the thrombotic lesions and a favourable patient outcome. Fibrinolytic therapy followed by angioplasty is a rational treatment alternative for inoperable or high risk patients in the case of concomitant mechanical valve and graft thrombosis.

**Keywords:** mechanical valve thrombosis, thrombolysis, myocardial infarction

## BACKGROUND

Prosthetic valve thrombosis (PVT) is a life-threatening complication of implanted mechanical valves, requiring immediate treatment. The incidence of left-sided PVT ranges from 0.1% to almost 6% and is predominantly triggered by inadequate anticoagulant therapy postoperatively (1, 2). Although surgical therapy is traditionally considered the most

effective therapeutic approach in management of stuck valves, recent data confirm that thrombolysis is a reasonable alternative to surgery, and superior in critical high-risk patients with PVT.

We present a case of aortic valve thrombosis successfully treated with alteplase followed by stenting of the left coronary artery.

## CASE PRESENTATION

A 71 year-old female patient was admitted to hospital with a history of two weeks of exertional dyspnea

---

Correspondence to: Ieva Norkienė, Vilnius University Hospital Santariškių Clinics, 2 Santariškių Street, LT-08448 Vilnius, Lithuania. E-mail: ievanork@gmail.com

(New York Heart Association (NYHA) class IV), which had progressively worsened for the past 2 days. She underwent mechanical aortic valve replacement (St Jude 21A) performed concomitantly with the saphenous venous graft to the left coronary artery one year ago. The patient was not using oral anticoagulation regularly over the last weeks. The international normalized ratio (INR) on admission was 1.5.

The patient was admitted to an intensive care unit, due to hemodynamic instability and tachypnea at rest, with a regular heart rate of 93 bpm and a supine blood pressure of 95/45 mmHg. Auscultation of the chest revealed bilateral moist rales and a systolic murmur in the aortic area and an early-diastolic murmur at the left parasternal border.

Her electrocardiogram showed sinus rhythm and non-specific intraventricular conduction delay. Chest radiography demonstrated pulmonary congestion.

Urgent transthoracic (TTE) and transesophageal (TOE) echocardiograms with the spectral Doppler recording of transvalvular blood flow were performed using a Vivid Five instrument (GE-Vingmed Ultrasound AS, Horten, Norway) with a multifrequency transducer.

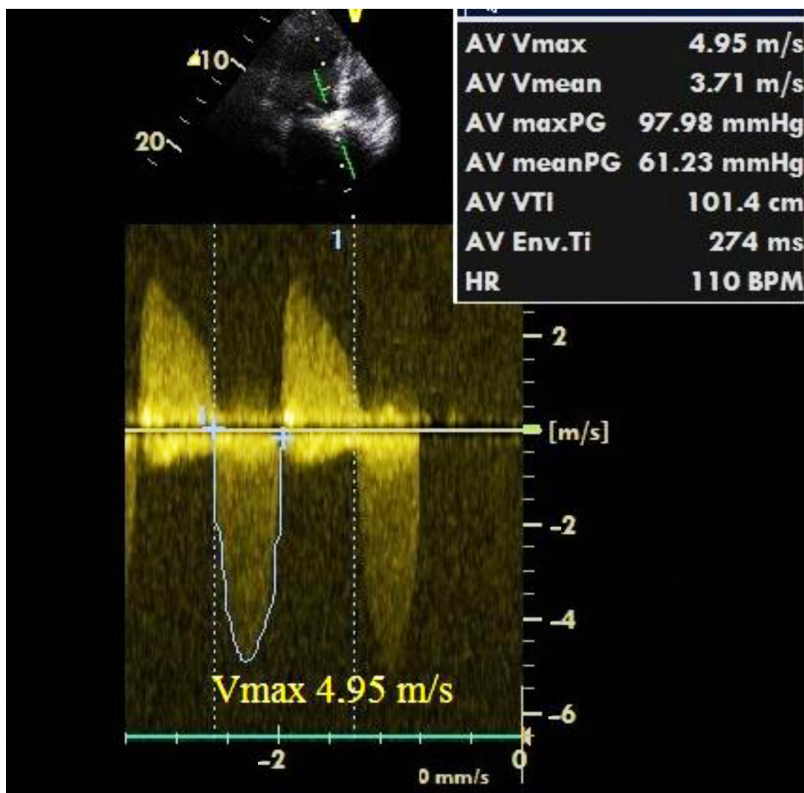
TTE and TOE suggested the restricted motion of aortic prosthetic leaflets with turbulent flow on the color flow Doppler scan (Fig. 1). Continu-

ous-wave Doppler echocardiography confirmed severe obstruction, with peak velocity through the prosthesis of 4.95 m/s (normal range for the prosthesis  $2.4 \pm 0.45$  m/s), and peak and mean gradients of 61 mm Hg and 100 mm Hg, respectively. The left ventricle was normal in size with a severely impaired systolic function (ejection fraction 25%). No obvious thrombus was seen on the aortic valve. Stuck aortic valve prosthesis was confirmed by fluoroscopic imaging. Also, because of increasing concentrations of cardiac troponin I (cTnI) up to 25.85 ng/l on arrival an acute coronary syndrome was presumed.

The patient's condition was rapidly worsening, with development of cardiogenic shock, she was intubated and inotrope infusions were commenced immediately.

The mortality risk of emergency aortic valve and bypass surgery estimated by EuroScore II was 51.3%. The decision was made to withhold surgical treatment, and after excluding the contraindications, proceed with fibrinolysis of the obstructed aortic valve and emergency percutaneous coronary angioplasty (PTCA) for suspected coronary graft thrombosis.

The patient was given 0.9 mg of alteplase (Actilyse, Boehringer Ingelheim) per kilogram, administered intravenously (with an upper limit of 100 mg). Of the total dose, 10% was administered as a bolus.



**Fig. 1.** Transesophageal echocardiography at admission revealed obstruction of the prosthetic bileaflet aortic valve. Spectral Doppler of aortic valve prosthesis

The rest was given by a continuous intravenous infusion over a period of 60 minutes. Heparin therapy was reinstated and continued after the thrombolysis for 48 hours.

Two hours after the initiation of thrombolysis, the patient's hemodynamic status started to improve. She was transferred for an emergency coronary angiogram, which showed the total occlusion of the venous graft to the left anterior descending artery (LAD). After predilation and stenting of occluded LAD (BMS Integrity 12A), restoration of TIMI 3 flow was achieved.

The control echocardiography with the spectral Doppler of flow through the prosthesis revealed an evident decrease in a mean systolic aortic transvalvular gradient of 17 mm Hg and a peak velocity of 2.79 m/s (Fig. 2).

The patient was extubated 24 hours after thrombolysis and on the fourth day discharged from the ITU in the clinically and hemodynamically stable condition.

Oral anticoagulation with warfarin sodium with target INR values of 2.5–3.5 and the concomitant use of aspirin were recommended to the patient. The patient improved clinically, with the exercise tolerance of NYHA II class and was successfully discharged from hospital 2 weeks from admission to our center.

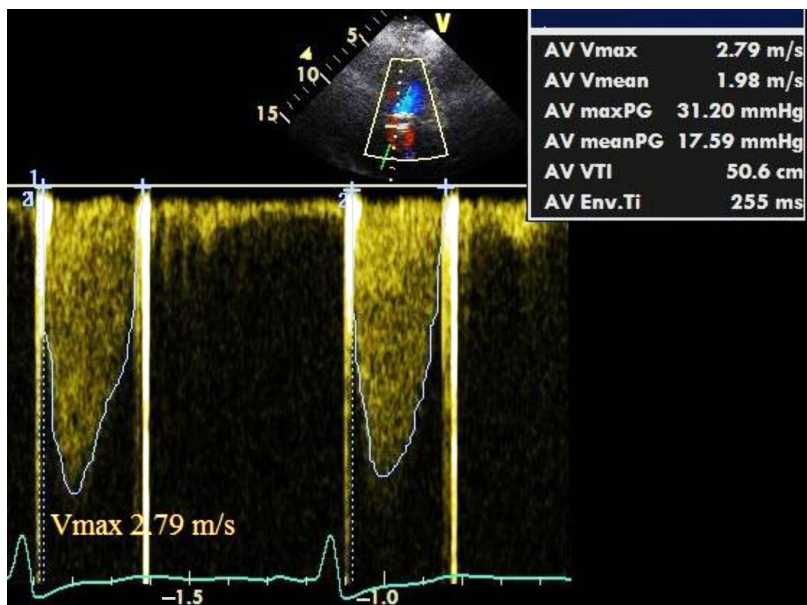
## DISCUSSION

Treatment of prosthetic valve thrombosis (PVT) remains controversial. Thrombolytic therapy, an-

ticoagulation, thrombectomy, or prosthetic valve surgical replacement are being considered as available treatment options in the modern era of cardiothoracic surgery. Despite the lack of randomized controlled prospective trials comparing surgery and thrombolytic therapy in the case of PVT, fibrinolysis has been recommended to critically sick patients with functional class III or IV, and high surgical operative risk as the class IIb recommendation (level of evidence: B) by ACC/AHA (1). The experience using thrombolysis has been summarized in recent European recommendations (2), review papers (3) and single center reports (4).

The obstructive PVT is a life-threatening condition, requiring immediate clinical decision. While the right-sided PVT thrombolysis carries no risk of cerebral embolism and the incidence of thromboembolism to the lungs is usually less serious, thrombolysis of the left sided PVT might result in severe neurological damage. Nevertheless, recent case series demonstrate that the left-sided thrombolysis of PVT can be conducted with the complete success rate in 70–80% of patients presenting in NYHA functional classes III/IV (5). As the dose and mode of administration of thrombolytic agents deviate, major complications are being observed in the rapid infusion protocols (6). In patients with PVT, slow infusion thrombolysis guided by serial transthoracic echocardiography and fluoroscopy may be achieved with a low risk of complications and a high rate of success.

We report a rare and life threatening case of stuck aortic valve and acute myocardial infarction. The fact



**Fig. 2.** Transthoracic echo and Doppler analysis demonstrating the improved flow through the aortic valve prosthesis after thrombolysis

that our patient was not using anticoagulation therapy has played a major role in development of the PVT.

In the setting of inadequate anticoagulation acute occlusive embolism to coronary arteries successfully treated with percutaneous transluminal coronary angioplasty (PTCA) in patients with mechanical prosthetic aortic valves has been described in random case reports (7).

In our case, a sequence of critical decisions that we had to make was determined by the worsening status of the patient. Before prioritizing thrombolysis before PTCA we estimated the risk and evaluated the expected benefit of the treatment. Successful treatment with thrombolysis and regained hemodynamic stability of the patient allowed us safe performance of PTCA and stenting of the completely occluded proximal left anterior descending artery.

## CONCLUSIONS

Our case demonstrates that thrombosis of the mechanical aortic valve concomitant with coronary graft occlusion leading to development of cardiogenic shock can be successfully treated with thrombolysis and subsequent PTCA.

Selection of optimal treatment should be tailored to patient's operative risk, thrombus location, risks of thrombolysis and clinicians' experience.

Received 23 February 2016

Accepted 21 March 2016

## References

1. Bonow RO, Carabello BA, Chatterjee K, de Leon AC Jr, Faxon DP, Freed MD, et al. ACC/AHA 2006 guidelines for the management of patients with valvular heart disease. *J Am Coll Cardiol.* 2006; 48(3): e1–148.
2. Vahanian A, Baumgartner H, Bax J, Butchart E, Dion R, Filippatos G, et al. Guidelines on the management of valvular heart disease: The Task Force on the Management of Valvular Heart Disease of the European Society of Cardiology. *Eur Heart J.* 2007; 28: 230–68.
3. Sun JC, Davidson MJ, Lamy A, Eikelboom JW. Antithrombotic management of patients with prosthetic heart valves: current evidence and future trends. *Lancet.* 2009; 374: 565–76.
4. Roudaut R, Lafitte S, Roudaut MF, Courtault C, Perron JM, Jaïs C, et al. Fibrinolysis of mechanical prosthetic valve thrombosis: a single-center study of 127 cases. *J Am Coll Cardiol.* 2003; 41: 653–8.
5. Huang G, Schaff HV, Sundt TM, Rahimtoola SH. Treatment of obstructive thrombosed prosthetic heart valve. *J Am Coll Cardiol.* 2013; 62(19): 1731–6.
6. Tong AT, Roudaut R, Ozkan M, Sagie A, Shahid MS, Pontes Jr SL. Transoesophageal echocardiography improves risk assessment of thrombolysis of prosthetic valve thrombosis: results of the International POR-TEE Registry. *J Am Coll Cardiol.* 2004; 43(1): 77–84.
7. Hernández F, Pombo M, Dalmau R, Andreu J, Alonso M, Albarrán A, Velázquez MT. Acute coronary embolism: angiographic diagnosis and treatment with primary angioplasty. *JC Catheter Cardiovasc Interv.* 2002; 55(4): 491–4.

**Ieva Norkienė, Ieva Kažukauskienė,  
Robertas Samalavičius, Kęstutis Ručinskas**

## SĖKMINGA TROMBOLIZĖ IR ANGIOPLASTIKA KOMBINUOTOS MECHANINIO AORTOS VOŽTUVO IR VAINIKINIŲ ARTERIJŲ ŠUNTO TROMBOZĖS ATVEJU

### Santrauka

Vožtuvo protezo trombozė – reta ir gyvybei pavojinga komplikacija, reikalaujanti skubaus gydymo. Optimalus obstrukcinės kairiosios širdies vožtuvo protezo trombozės gydymas yra kontroversiškas ir priklauso nuo paciento būklės, įvertintos operacinio gydymo rizikos, trombo lokalizacijos ir dydžio bei gydančių gydytojų patirties. Straipsnyje pristatomas klinikinis 71 metų pacientės, hospitalizuotos progresuojant ūmiam širdies nepakankamumui, atvejis. Transezofaginės echoskopijos metu nustatyta ūmi obstrukcinė mechaninio aortos vožtuvo trombozė. Besivystančio ūmaus miokardo infarkto požymiai leido įtarti vainikinės kraujagyslės šunto trombozę. Trombolizė, taikant alteplazę, ir vėlesnis vainikinės jungties stentavimas buvo sėkmingi. Konservatyvus gydymas fibrinolitikais ir angioplastika – tinkamas pasirinkimas, garantuojantis gerus gydymo rezultatus, didelės rizikos neoperabiliems pacientams.

**Raktažodžiai:** mechaninio aortos vožtuvo trombozė, trombolizė, miokardo infarktas