

# The multimodal treatment of rectocele

## Daugiamodulus rektocelės gydymas

Xavier Delgadillo-Pfenninger

*Coloproctology Unit – EBSQ Coloproctology-Clinique Montbrillant, La Chaux-de-Fonds: Switzerland Joseph Nunoo-Mensah*  
*E-mail: j.nunoo-mensah@crsurgeon.co.uk*

### Introduction

Obstructed defecation syndrome (ODS) and chronic constipation syndrome (CCS) are common and complex problems caused by different entities such as enterocele, rectocele, pelvic dyssinergy, rectal intussusception, internal mucosal-rectal prolapse, and many others. These entities cause changes that delay the passage of the bowel content.

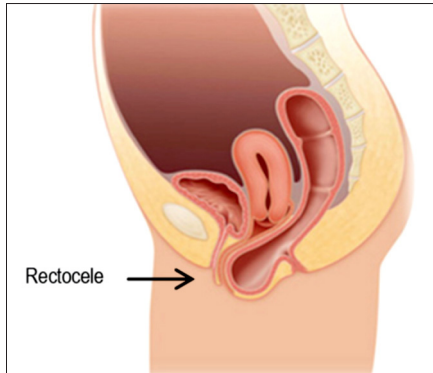
Surgical management of these conditions requires an advanced understanding of defecatory, sexual, and urinary functionality to achieve optimal results, with the final aim focused on restoring the functionality and anatomic repositioning of all the organs concerned. As described by Ellis and Essani [1], optimal outcomes can only be achieved by selecting appropriate treatment modalities that address all of the components of a patient's problem. The complexity of ODS and CCS warrants the interdisciplinary work-up and treatment as mentioned by Ambe and Köhler [2].

The diagnosis includes the patient's general and specific symptoms (changes of life style, abuse of laxatives, painful intercourse, effort urine leakage). It is useful to create a standardized scoring system of the disease.

Many authors (Altomare, Wexner, Longo and many others) had proposed many different scores trying to establish a specific pattern. A special examination must be performed in association with a gynaecologist in female patients with complex pelvic floor disorders. Endoscopic examination (anoscopy, rectoscopy and colonoscopy) is mandatory, a radiological standard defecography (eventually MRI) is recommended. Endorectal ultra-sound is a complementary imaging study to determine puborectal disorders. Anal manometry must be performed to prevent any disorder after the operation concerning the possibility of paradoxal incontinence. Biofeedback, pelvic floor physiotherapy are mandatory procedures before surgery.

### Definition

Rectocele can be defined as a *hernia* of the anterior rectal wall (as a result of a rheologic protrusion) through the posterior vaginal wall as a result of an elevated pressure (rheology) on the recto-vaginal structure due to an increased volume and the resulting pushing force of stools, originating a protrusion of the entire anterior rectal wall as described in diagram (Figure 1).

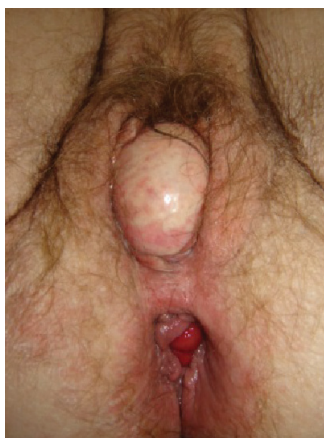

**Figure 1.** Diagram of rectocele and « cul de sac Douglas descent (Image by M.-C. Marti)

## Clinical findings

Rectocele causes an important *sequestre* of stools in this protruded resultant compartment that will evolve into a big volume mass. This effect has also been described as a *prolapse* when it is exteriorized during defecation. Frequently it is associated to a descending of the surrounding structures, causing a rectal intussusception. This entity, known as rectal invagination, is the “head of the iceberg” described more than 20 years ago by M. Pescatori and reviewed by the same author early in 2007 [3].

More recently, colorectal surgeons have agreed that the rectocele’s structure is the main cause of ODS and an indirect cause of CCS. From another point of view,



**Figure 2.** Rectocele grade 3 associated with a mucosal anal prolapse (photo by X. Delgadillo)

gynaecologists call this protrusion *posterior colpocele* (v.g. Greek colpos = vaginal), frequently followed by the *fonds de sac* of Douglas and more often associated with small bowel or the sigmoid loops.

Many different techniques and a variety of procedures have been described for the treatment of ODS following an important academic interest, i.e. what we have defined as *technical shopping*.

Every author and promoter of a new and innovative technique presents their own procedure as the “best of all others”, and they advertise their results as a promising future result of the “unique technique” better than ever and over the others. That is what we have called *surgical marketing*.

However, behind each concept of rectocele there are many hidden entities with a direct *liason* with the histopathological point of view.

## Surgical treatment

Surgical procedures for ODS, CCS have significantly evolved during the last 20 years, increasing the understanding of anatomy, pathophysiology and allowing the advent of new minimally invasive endoscopic or laparoscopic procedures. Pelvic floor repair requires a thorough knowledge of pelvic floor anatomy and its supportive components before the repair of a defective anatomy as suggested by D’Hoore this year [4].

Surgery is indicated for all those patients when no improvement of symptoms is really evident and when the medical treatment is not effective (biofeedback and pelvic floor physiotherapy, bowel transit regulators, instrumental therapy), when patients present an incomplete defecation, unsuccessful attempts with long periods spent in toilets, defecation with digital assistance, use and abuse of enemas, and a lower quality of life [5].

Many approaches have been described during the last twenty years, such as open surgery fixations, perineal combined boards, endo-anal and trans-anal boards, laparoscopic procedures, and many others.

Actually, advantageous techniques are well considered when they bring solutions within an effective anatomical result, short hospital stay, reduced postoperative pain, predictable functional results, a short off-work period, safety procedures by performed trained surgeons, well selected patients and lower costs of instruments needed.

### 1. Abdominal laparoscopy

All procedures described in the past in the laparotomy approach are nowadays performed by laparoscopic techniques.

Actually, many surgeons have developed their own approaches, but they remained classic, like Zaccharin, when he presented his abdomino-perineal procedure late in the 80s, and like us (in association with B. Roche from Geneva) adapted a couple of tips and tricks proposed by my Master M.-C. Marti [8], resulting in a combined procedure that we called Marti–Zaccharin (MCMZ).

Actually, we had abandoned the MCMZ procedure for more classic and standardized procedures such as the ventral fixation of the rectum as described by F. Peninckx [6] from Belgium late in 2006 and followed by A. D’Hoore in the same way, and more recently [4]. Sometimes and depending on the patients’ needs, we add a ventral mesh for a definitive fixation.

### 2. Perineal techniques

One of the most frequent techniques used to correct the rectocele by a perineal (ano-vulvar) approach is an access to the *rrhaphé median du périnée* region. This is available by an incision on the lower vaginal *introitus* and dissecting by a vertical or horizontal exposure the recto-vaginal space, seeking to separate the virtual structure of the recto-vaginal septum. This manoeuvre permits to identify the levatorian muscles in their both aspects and to perform a posterior colporrhaphy. Our preferred method to correct the rectocele is as described by gynaecologists [7] many years ago (1972) for a severe rectocele and perineal lacerations.

On the other hand, passing-by the dissection of the vaginal *introitus*, it is well known that a *plicature* as a *bourse à tabac* or in a Venetian store can be performed to make a correction of a disabled rectocele. This proce-

dure has been well described by the team of P. A. Lehur [9] in France early in the 90s.

### 3. Endoanal techniques

At the beginning, Delorme described the endoanal approach, but a significant statistical recurrency obligated the pelvic floor surgeons to abandon it [5]. More recently, new advantageous techniques have offered a solution with an effective anatomical result by an endoanal approach. They have an important advantage over the other more invasive techniques in terms of a short hospital stay, reduced postoperative pain, predictable functional results, and a short off-work period.

On the other hand, some disadvantages are to be considered in case of safety, because all those endoanal procedures like the stapled transanal rectocele resection (STARR) [10] and more recently the Trans-STARR Contour® are the procedures that must be performed by really well-trained and specialized surgeons. This procedure should be performed on well selected patients and it should be considered about their high costs of the disposable material and instruments.

### Conclusions

There are some important issues that we should not forget, and these are [11]:

- I. Treatment of pelvic floor disorders is a complex task because of many different symptoms, anatomical manifestations and more frequently intricated functional outcomes.
- II. The anatomical repositioning and correction of structures does not correct the functional problems.
- III. The treatment of rectocele, ODS, CCS is multimodal, and surgery is just a step on the large and long way to success.
- IV. Great results and fantastic outcomes can degrade extremely fast during a short-term follow-up, requiring long-term surveillance to manifest definitive optimal results.

## REFERENCES

1. Ellis CN, Essani R. Treatment of obstructed defecation. *Clin Colon Rectal Surg* 2012 ; 25(1): 24–33.
2. Ambe P, Weber SA, Esfahani BJ, Köhler L. Surgical options in the treatment of the obstructed defaecation syndrome. *Deutsch Med Wochenschr* 2011; 136(12): 586–590.
3. Pescatori M, Spyrou M, Pulvirenti d'Urso A. A prospective evaluation of occult disorders in obstructed defecation using the 'iceberg diagram'. *Colorectal Dis* 2007 Jun; 9(5): 452–456.
4. Van Gelluwe B, Wolthuis A, D'Hoore A. Laparoscopy for pelvic floor disorders. *Best Pract Res Clin Gastroenterol* 2014; 28(1): 69–80.
5. Ohazuruike NL, Martellucci J, Menconi C, Panicucci S, Toniolo G, Naldini G. Short-term results after STARR vs Internal Delorme for obstructed defecation. *Updates Surg* 2014;16s.
6. D'Hoore A, Penninckx F. Laparoscopic ventral recto(colpo) pexy for rectal prolapse: surgical technique and outcome for 109 patients. *Surg Endosc* 2006 Dec; 20(12): 1919–1923.
7. Pratt JH. Surgical repair of rectocele and perineal lacerations. *Clin Obstet Gynecol* 1972 Dec; 15(4):1160–1172.
8. Marti MC. Rectocele: a complete review. *Ann Gastroenterol Hepatol (Paris)*. 1989 Dec; 25(7): 309–311.
9. Lehur PA, Bruley Des Varannes S, Moyon J, Guiberteau-Canfrere V, Le Borgne J. Disabling rectocele: rectal plication by perineal approach. Apropos of 20 cases. *Chirurgie* 1992;118(9): 516–520.
10. Ribaric G, D'Hoore A, Schiffhorst G, Hempel E. STARR-Contour® TRANSTAR™ device for obstructed defecation syndrome: one-year real-world outcomes of the European TRANSTAR registry. *Int J Colorectal Dis* 2014 Feb 21.
11. Delgadillo X., Roche B. *Practical Proctology*. Med & Hyg Eds. 2007 Chapter 2; p. 33–39.