

# Heart perforation by pacemaker: a case report

## Širdies perforacija elektrokardiostimulatoriumi: klinikinis atvejis

Lina Pankratjevaitė<sup>1</sup>, Diana Samiatina-Morkūnienė<sup>2</sup>

<sup>1</sup> Department of Surgery, Medical Academy, Hospital of Lithuanian University of Health Sciences

<sup>2</sup> Department of Thoracic Surgery, Medical Academy, Hospital of Lithuanian University of Health Sciences, Eivenių Str. 2, LT-50009 Kaunas, Lithuania  
E-mail: dsamiatina@yahoo.de

<sup>1</sup> Lietuvos sveikatos mokslų universiteto ligoninė, Medicinos akademija, Chirurgijos skyrius

<sup>2</sup> Lietuvos sveikatos mokslų universiteto ligoninė, Medicinos akademija, Krūtinės chirurgijos skyrius, Eivenių g. 2, LT-50009 Kaunas  
El. paštas: dsamiatina@yahoo.de

---

### Background

Cardiac perforation is a rare complication of pacemaker or implantable defibrillator implantation. Patients with cardiac perforation may present with various symptoms, and sometimes it creates real diagnostic difficulties.

### Case report

We report the case of an 80-year-old patient with a sick sinus syndrome. He underwent the implantation of a dual chamber permanent pacemaker complicated by cardiac perforation, haemopericardium, and right haemothorax. The patient felt unwell a few hours after the procedure had been done. However, the cardiac perforation was confirmed by chest computed tomography just five days after the pacemaker implantation had been performed. Migrated lead was removed by an electrophysiologist with the backup of surgeons under thoracoscopy control. Next day the migrated lead was changed with a new one, and the patient left the hospital on the sixteenth day after pacemaker implantation.

### Conclusions

Literature says that the big part of migrated pacemakers' leads could be removed safely by simple traction under X-ray or echocardiography monitoring in the operating room, with a surgeon team backup. We have done it successfully with a thoracoscope control.

**Key words:** pacemaker, complications, cardiac perforation, thoracoscopy

---

### Įvadas

Viena iš retų elektrokardiostimulatoriaus ar defibriliatoriaus implantacijos komplikacijų yra širdies perforacija. Jos klinikinės išraiškos pasižymi didele įvairove ir gali sukelti daug diagnostikos sunkumų.

### Klinikinis atvejis

Į mūsų ligoninę dėl sinusinio mazgo silpnumo sindromo hospitalizuotas 80 metų ligonis. Jam implantuotas dviejų kamerų ilgalaikis kardiostimulatorius. Procedūros komplikacijos – širdies perforacija, hemoperikardiumas ir dešinės pusės hemotoraksas. Po procedūros praėjus kelioms valandoms, ligonis pasijuto blogai, tačiau tiksliai širdies perforacijos diagnozė nustatyta

tik penktą dieną po kardiostimulatoriaus implantavimo, kai atlikta krūtinės ąstos kompiuterinė tomografija. Tuomet elektrofiziologas, padedamas chirurgo, kontroliuojant procedūrą torakoskopu, pašalino migravusį elektrokardiostimulatoriaus elektrodą. Kitą dieną ligoniui įdėtas naujas elektrodas. Praėjus šešiolikai dienų po elektrokardiostimulatoriaus implantavimo, vyras išrašytas iš ligoninės.

### **Išvados**

Literatūroje minima, kad dauguma migravusių elektrodų gali būti paprastai ištraukti kontroliuojant procedūrą rentgenu ar stebint echokardiografu operacinėje, kartu esant pasirengusiai chirurgo komandai. Mes sėkmingai pašalinome elektrodą kontroliuodami procedūrą torakoskopu.

**Reikšminiai žodžiai:** elektrokardiostimulatorius, komplikacijos, širdies perforacija, torakoskopija

---

## **Introduction**

Pacemakers and implantable defibrillators are increasingly being used to treat various cardiac arrhythmias. However, they can have severe complications such as pneumothorax, cardiac perforation, pericardial effusion, haemothorax, etc. [1, 2, 3]. Heart perforation and haemothorax is a very rare complication of pacemaker implantation [3]. Heart perforation can be acute (occurs within 24 h after implantation), subacute (up to one month) and delayed lead perforation [4, 5]. Patients with cardiac perforation can be asymptomatic or expose cardiac tamponade and even death [6]. Chest X-ray, echocardiography and chest computed tomography (CT) scanning can be helpful to prove or deny heart perforation [7, 8]. Chest X-ray can be helpful to evaluate the possible leads migration outside the heart. When chest X-ray and echocardiography are negative, but cardiac perforation is suspected, chest CT scan is recommended [8]. In literature, there is mentioned that the big part of migrated leads could be removed safely by simple traction under X-ray or with echocardiography monitoring in the operating room, of course with a surgeon team backup [9]. Surgery is performed just in those cases when heart tamponade is present or the location of migrated lead is atypical [9]. We report the case of an 80-year-old patient with cardiac perforation, haemopericardium and right haemothorax caused by the pacemaker. Migrated lead was removed by an electrophysiologist with the backup of surgeons under thoracoscopy control.

## **Case report**

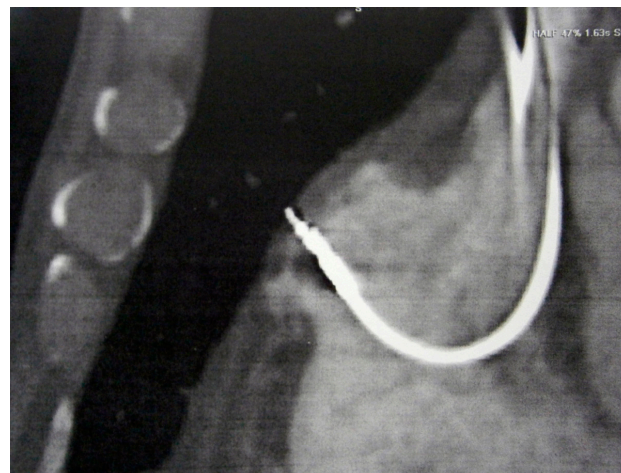
An 80-year-old man was admitted to the Cardiology Department of our hospital because of his syncope, diz-

ziness. His past medical history was significant for three years lasting bradycardia (lowest heart rate was 35 times per min), about one-year recurrent atrial fibrillation paroxysms, arterial hypertension lasting about twenty years. During physical examination, his blood pressure was 170/90 mmHg and heart rate 60 times per min. His electrocardiography (ECG) showed sinus rhythm, left bundle branch block, extrasystoles. Blood laboratory findings were within normal limits (white blood cells (WBC)  $4.92 \times 10^9/l$ , red blood cells (RBC)  $4.64 \times 10^{12}/l$ , haemoglobin (HGB) 144 g/l, platelets (PLT)  $176 \times 10^9/l$ ). Doctors diagnosed him with the sick sinus syndrome (also called sinus node dysfunction), and he underwent the implantation of a dual chamber permanent pacemaker (Medtronic, Vitatron E60A1). The patient complained of a chest pain irradiating to the abdomen few hours after the implantation. His blood pressure got unmeasurable. Bleeding and heart tamponade were suspected. Chest X-ray was done, but it was without important changes. An urgent 2D echocardiography revealed a 1 cm liquid around the heart without tamponade. Because of unstable hemodynamics the patient was moved to the Cardiology Intensive Care Unit where analgesics, infusion therapy and vasopressors were administered. Echocardiography was repeated – fluid around the heart did not increase. The patient's hemodynamics got stable, the pain disappeared, and the patient was returned to the Cardiology Department after one day he spent in the Cardiology ICU. His blood test was repeated, and it was with changes (HGB decreased from 144 g/l to 120 g/l; RBC from  $4.64 \times 10^{12}/l$  to  $3.99 \times 10^{12}/l$ ). Next day the patient again complained of chest and abdomen pain. His ECG revealed tachysystolic atrial fibrillation (145 times per min), blood pressure decreased to 72/43 mmHg. The patient was again moved

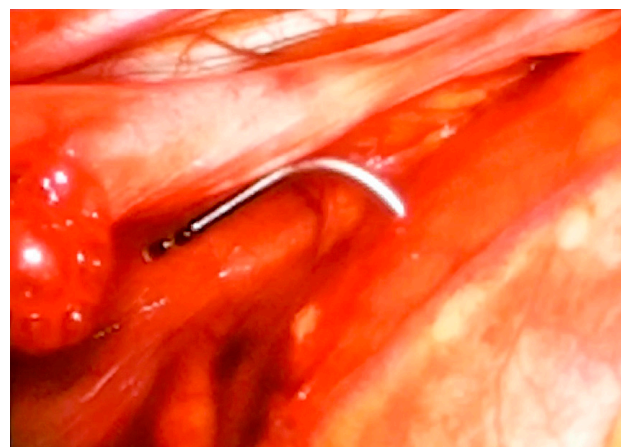
to the Cardiology ICU. His sinus rhythm was restored, but the pain syndrome remained. His blood HGB (to 110g/l) and RBC (to  $3.5 \times 10^{12}/l$ ) were still decreasing, but WBC grew up (to  $12.79 \times 10^9/l$ ). The abdomen ultrasound revealed a thickened gall bladder wall, that is why cholecystitis was suspected and the conservative treatment was administered. But the pain of chest and abdomen continued. Then the chest X-ray was repeated, and it revealed infiltration and hypoventilation in the bottom of the right lung. After that, for the first time a thoracic surgeon consulted the patient – he drained the right pleural cavity and got about 300 ml of dark, not clotting blood (the patient was stable – blood pressure 140/90 mmHg). Then the chest ultrasound was done, and about 700 ml free fluids in the pleural cavity were seen. A 2D echocardiography was done, too, but it did not show any heart tamponade. Heart perforation was suspected, and chest computed tomography (CT) was performed to prove it (it was the fifth day after the pacemaker implantation). CT showed ~3.3cm thick free fluid strip in the pleural cavity, and one of the two pacemaker leads was 2–3 mm behind the pericardium area (Fig. 1). In both sides of the pleural cavities there was free fluid (right ~5 cm, left ~2.5 cm). Blood HGB was already decreased to 95 g/l and RBC to  $3 \times 10^{12}/l$ . Then thoracoscopy was done. During the surgery, about 1200 ml of dark blood and clots were removed from the right pleural cavity. A ~6 cm long foreign body (pacemaker lead) was migrated from the right atrium and leaned on the right lung upper lobe (Fig. 2). The electrophysiologist removed the electrode with the help of thoracic surgeons under thoracoscopy control. There was no active bleeding from the heart. Haemostasis was performed with a special tampon. The pleural cavity was drained with two drains. The operation was without complications. The next day, the right atrium-dislocated lead was successfully changed with a new one. On sixteenth day after pacemaker implantation the patient left the hospital.

## Discussion

Iatrogenic injuries can occur in all interventional procedures. Complications associated with implantation of a pacemaker or implantable defibrillator include cardiac perforation, pericardial effusion, pneumothorax,



**Figure 1.** Computed tomography picture shows heart perforation by pacemaker lead



**Figure 2.** During the thoracoscopy ~6 cm long migrated pacemaker lead was seen

haemothorax [1, 2, 3]. The heart perforation with pacemaker leads is a rare complication – the incidence ranges from 0.1% to 0.8% [10]. The rate of perforation may be influenced by the lead design, doctor experience and factors related to the patient (age, low body mass index, anticoagulation therapy, use of steroids) [11, 12, 13].

It is important to mention that the perforation can be acute, subacute, and delayed lead perforation [4, 5]. It may be asymptomatic or have various symptoms: chest pain, abdominal pain, dyspnoea, syncope, or present as a sudden cardiac death [4, 8, 14]. To diagnose heart perforation, chest X-ray, echocardiography and chest CT are used [5, 7, 8, 9, 15]. When the chest X-ray and

echocardiography are negative but cardiac perforation is suspected, the chest CT scan is recommended [8, 16]. Literature says that the CT scan is a golden standard [5]. Of course, a minus of the CT scan is a big radiation dose. In our case, the patient felt unwell (complained of chest pain irradiating to the abdomen) a few hours after the implantation, but heart perforation was confirmed by a CT scan just five days after the procedure had been performed. However, heart perforation was suspected at the beginning, but a radiological test like chest X-ray or echocardiography did not reveal any perforation, and doctors had diagnostic difficulties.

Furthermore, a possibility of leads migration and cardiac perforation may indicate the inappropriate pacemaker function [8]. But it is very important that the pacemaker can function normally even if there is heart perforation [4, 8].

In literature, it is mentioned that the big part of migrated leads could be removed safely by a simple traction under X-ray or with echocardiography monitoring in the operating room with the surgeon team backup [2, 5, 9, 17,18]. Surgery is performed just in the cases when heart tamponade is present or the location of the

migrated lead is atypical [5, 9]. In this case, the migrated lead was removed by the electrophysiologist with the backup of surgeons under thoracoscopy control.

## Conclusions

Cardiac perforation is a rare complication of a pacemaker or an implantable defibrillator implantation. Its clinical manifestation is variable and sometimes creates diagnostic difficulties. Chest X-ray, echocardiography and chest CT scanning can be helpful to prove or deny heart perforation. When chest X-ray and echocardiography are negative, the chest CT scan is recommended for diagnosing heart perforation. It is important to know that the normal pacemaker electrophysiological function does not exclude heart perforation. The big part of migrated pacemakers' leads could be removed safely by a simple traction under X-ray or echocardiography monitoring in the operating room, with the surgeon team backup. In our case, the migrated lead was successfully removed by the electrophysiologist under the thoracoscopic control. Literature says the operation treatment is performed just in the cases when the heart tamponade is present or the location of the migrated lead is atypical.

## REFERENCES

1. Schiariti M, Cacciola M, Puddu PE. Complications of Pacemaker Implantation. In: *Modern Pacemakers – Present and Future*. Prof. Mithilesh R Das (ed.). 2011. ISBN: 978-953-307-214-2, InTech. Available from: <http://www.intechopen.com/books/modern-pacemakers-present-andfuture/complications-of-pacemaker-implantation>.
2. Aykan HH, Akin A, Ertuğrul I, Karagöz T. Delayed right-ventricular perforation by pacemaker lead; a rare complication in a 12-year-old girl. *Türk Kardiyol Dern Arş – Arch Turk Soc Cardiol* 2015; 43(2): 185–7. Available from: doi:10.5543/tkda.2015.98372
3. Nichols J, Berger N, Joseph P, Datta D. Subacute right ventricle perforation by pacemaker lead presenting with left hemothorax and shock. *Case Reports in Cardiology*. Vol. 2015, Article ID 983930, 4 pages. Available from: <http://dx.doi.org/10.1155/2015/983930>.
4. Rydlewska A, Małecka B, Ząbek A, Klimeczek P, Lelakowski J, Pasowicz M, Czajkowski M, Kutarski A. Delayed perforation of the right ventricle as a complication of permanent cardiac pacing – is following the guidelines always the right choice? Non-standard treatment – a case report and literature review. *Kardiologia Pol* 2010; 68: 357–61.
5. Piekarczyk J, Lelakowski J, Rydlewska A, Majewski J. Heart perforation in patients with permanent cardiac pacing – pilot personal observations. *Arch Med Sci* 2012; 8 (1): 70–74. DOI: 10.5114/aoms.2012.27284.
6. Park HK, Ahn HS, Lee BS, Won HJ, Byun YS, Goh CW, Kim BO, Rhee KJ, Lee BK. Early detection of perforation of the right ventricle by a permanent pacemaker lead. *Korean Circulation J* 2007; 37: 453–7.
7. Nash G, Williams JM, Nekkanti R, Movahed A. Case of early right ventricular pacing lead perforation and review of the literature. *World Journal of Clinical Cases: WJCC*. 2014; 2(6): 206–8. doi:10.12998/wjcc.v2.i6.206.
8. Chryssagis K, Abdallah A. Life-threatening perforation of pacemaker atrial lead through the right atrium and the right lung. *J Cardiol Curr Res* 2015; 2(6): 00079. DOI:10.15406/jccr.2015.02.00079.
9. Oh S. Cardiac perforation associated with a pacemaker or ICD lead. In: *Modern Pacemakers – Present and Future*. Prof. Mithilesh R Das (ed.). 2011. ISBN: 978-953-307-214-2, InTech. Available from: <http://www.intechopen.com/books/modern-pacemakers-present-and-future/cardiac-perforation-associated-with-a-pacemaker-or-icd-lead>.

10. Carlson MD, Freedman RA, Levine PA. Lead perforation: incidence in registries. *Pacing Clin Electrophysiol* 2008; 31: 13–15.
11. Sterlinski M, Przybylski A, Maciag A, Syska P, Pytkowski M, Lewandowski M, Kowalik I, Firek B, Kołsut P, Religa G, Kusmierczyk M, Walczak F, Szwed H. Subacute cardiac perforations associated with active fixation leads. *Europace* 2009; 11(2): 206–212. DOI:10.1093/europace/eun363.
12. Hermanides RS, Ottervanger JP, Elvan A, Ramdat Misier AR. Life-threatening perforation of a defibrillation lead. *Neth Heart J* 2009; 17(3): 113–4.
13. Barold SS, Stroobandt RX, Sinnaeve AF. Pacing lead perforation on the right side of the heart. *Türk Aritmi, Pacemaker ve Elektrofizyoloji Dergisi CİLT 7, SAYI 2, Haziran 2009*: 100–4.
14. Laborderie J, Barandon L, Ploux S, Deplagne A, Mokrani B, Reuter S, Le Gal F, Jais P, Haissaguerre M, Clementy J, Bordachar P. Management of subacute and delayed right ventricular perforation with a pacing or an implantable cardioverter-defibrillator lead. *Am J Cardiol* 2008; 102: 1352–55.
15. Stefanidis AS, Margos PN, Kotsakis AA, Papasteriadis EG. Three-dimensional echocardiographic documentation of pacemaker lead perforation presenting as acute pericarditis. *Hellenic J Cardiol* 2009; 50(4): 335–7.
16. Henrikson CA, Leng CT, Yuh DD, Brinker JA. Computed tomography to assess possible cardiac lead perforation. *Pacing and Clinical Electrophysiology* 2006; 29(5): 509–11.
17. Sadamatsu K. Complication of Pacemaker Implantation: An Atrial Lead Perforation. In: *Modern Pacemakers – Present and Future*. Prof. Mithilesh R Das (ed.). 2011. ISBN: 978-953-307-214-2. InTech. Available from: <http://www.intechopen.com/books/modern-pacemakers-present-and-future/complication-of-pacemakerimplantation-an-atrial-lead-perforation>.
18. Banaszewski M, Stepińska J. Right heart perforation by pacemaker leads. *Archives of Medical Science* 2012; 8: 11–13.