

# Neuromyelitis Optica Spectrum Disorder: A Case Report

**Paulius Sėdžius**Department of Neurology, Lithuanian University of Health  
Sciences, Kaunas, Lithuania**Rymantė Gleiznienė**Department of Radiology, Lithuanian University of Health  
Sciences, Kaunas, Lithuania**Gintarė Šataitė**Department of Neurology, Lithuanian University of Health  
Sciences, Kaunas, Lithuania**Dalia Musneckienė**Department of Neurology, Lithuanian University of Health  
Sciences, Kaunas, Lithuania

**Summary.** *Neuromyelitis Optica Spectrum Disorder* (NMOSD) is a rare inflammatory and demyelinating disease of the central nervous system affecting the optic nerves and the spinal cord. Diagnosis of NMOSD is based on the Diagnostic Criteria of the *International Panel for NMOSD diagnosis* (IPND). This paper introduces the case of a man who developed bilateral blindness and acute paralysis of legs. The MRI scan of the brain and spinal cord revealed lesions characteristic of transverse myelitis and bilateral optic neuritis. The serum test performed was negative for aquaporin-4-IgG (AQP4-IgG). Based on the diagnostic criteria of IPND, the patient was diagnosed with NMOSD and prescribed with immunosuppressive methylprednisolone IV once a day for five days and changed to prednisolone PO. The clinical case described here demonstrates the importance of assessing the clinical symptoms as well as brain and spinal cord images in the diagnosis of NMOSD in seronegative AQP4-IgG patients.

**Keywords:** Neuromyelitis Optica Spectrum Disorder, aquaporin-4 antibodies.

## Optinio neuromielito spektro sutrikimas – atvejo analizė

**Santrauka.** Optinio neuromielito spektro sutrikimas – reta uždegiminė demielinizuojanti centrinės nervų sistemos liga, pažeidžianti regos nervus ir nugaros smegenis. Liga diagnozuojama remiantis tarptautiniais optinio neuromielito spektro sutrikimų komisijos diagnostiniais kriterijais. Šis straipsnis pristato atvejį vyro, kuriam pasireiškė abipusis aklumas ir ūmus kojų nevaldymas. Galvos ir nugaros smegenų magnetinio rezonanso tomografijos tyrimu aptikti pokyčiai buvo būdingi skersiniam mielitui ir abipusiam optiniam neuritui. Serumo tyrime teigiamų antikūnų prieš akvaporiną-4 nerasta. Remiantis tarptautiniais optinio neuromielito spektro sutrikimų komisijos diagnostiniais kriterijais buvo nustatyta diagnozė – optinio neuromielito spektro sutrikimas – ir paskirtas imunosupresinis gydymas intraveniniu metilprednizolonu penkis dienas, vėliau skirtas prednizolonas tabletėmis. Pristatytas klinikinis atvejis parodė, kaip svarbu vertinti klininius simptomus, galvos ir nugaros smegenų vaizdinius tyrimus nustatant optinio neuromielito spektro sutrikimą esant neigiamiems akvaporino-4 antikūnams serume.

**Raktažodžiai:** optinio neuromielito spektro sutrikimas, akvaporino-4 antikūnai.

\* **Address:** Paulius Sėdžius, Department of Neurology, Lithuanian University of Health Sciences, Kaunas, Lithuania, Eivenių 2, LT-50161, Kaunas, Lithuania. Phone +370 621 84 166, E-mail: paulius.sedzius@stud.lsmu.lt

**Received:** 30/01/2025. **Accepted:** 28/02/2025

Copyright © Paulius Sėdžius, Gintarė Šataitė, Rymantė Gleiznienė, Dalia Musneckienė, 2024. Published by Vilnius University Press. This is an Open Access article distributed under the terms of the Creative Commons Attribution License, which permits unrestricted use, distribution, and reproduction in any medium, provided the original author and source are credited.

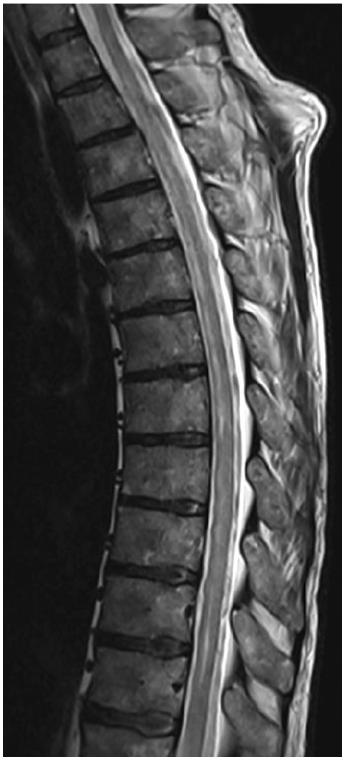## Introduction

Neuromyelitis optica spectrum disorder is an autoimmune disease characterized by *Optic Neuritis* (ON), *Longitudinally Extensive Transverse Myelitis* (LETM), and brainstem damage [1]. The term ‘acute optic neuromyelitis’ was first used by the French neurologist Eugène Devic in 1894 to describe a novel syndrome. Discovery of aquaporin-4 (AQP4) antibody, as well as clinical and *Magnetic Resonance Imaging* (MRI) findings of NMOSD have led to it being recognized as a separate disease from multiple sclerosis. Diagnosis of NMOSD is based on the Diagnostic Criteria of the International Panel for NMOSD diagnosis updated by the Neuromyelitis Optica Study Group in 2023. The criteria also introduced the possibility of a ‘seronegative NMOSD’ to facilitate diagnosis in patients with unknown AQP4 IgG serostatus, if strict clinical and MRI requirements are met [2,3]. Presently, we shall discuss this rare disorder contextualized with the available literature.

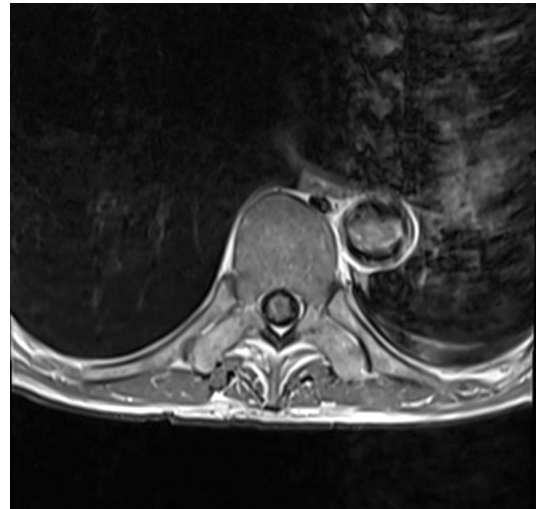
## Case Report

A 69-year-old patient was admitted to the Emergency Department of our hospital on September 19, 2024, due to blindness, complete paralysis of both legs, and dysfunction of the pelvic organs persisting for approximately one week. Before the transfer, the patient had been examined at the *Emergency Care Unit* (ECU) of a peripheral hospital: a *Computed Tomography* (CT) scan of the brain, thoracic and lumbosacral spinal cord revealed no acute abnormalities.

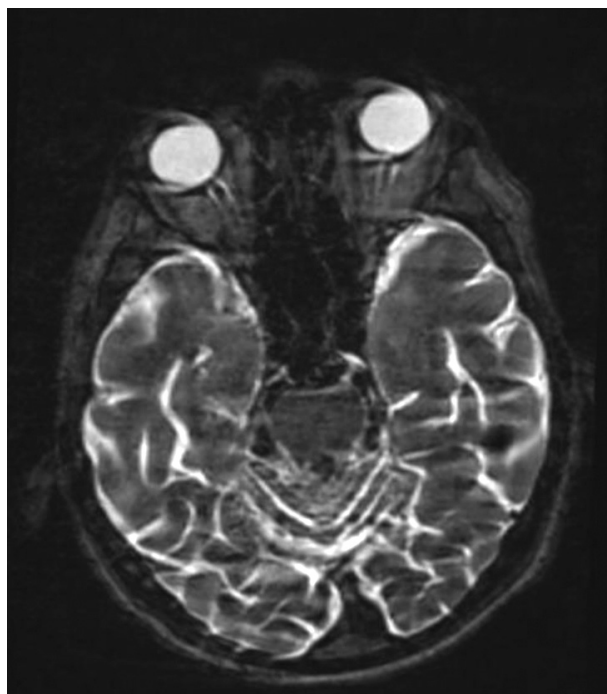
In the presence of bilateral blindness, leg paraplegia, atony, leg areflexia and anesthesia from the 9<sup>th</sup> thoracic segment, *Magnetic Resonance Imaging* (MRI) of the thoracolumbar spinal cord was performed at the Emergency Care Unit of Kaunas Clinics, which revealed a suspected diffuse myelopathy (transverse myelitis) at the level of Th9-L1 with accumulation of the contrast agent; see (Fig. 1) and (Fig. 2).



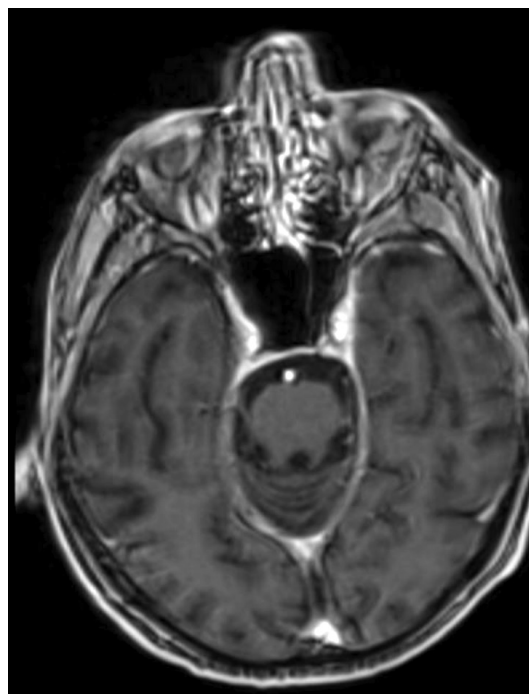
**Fig. 1.** Sagittal MRI STIR sequence, suspected diffuse myelopathy (transverse myelitis) at the TH9/L1 level. *Meddream images from the Hospital of the Lithuanian University of Health Sciences Kaunas Clinics*



**Fig. 2.** MRT post-contrast transverse T1 sequence. Suspected peripheral semicircular accumulation of contrast agent at the Th9/10 level, less pronounced at the Th11 level. *Meddream images from the Hospital of the Lithuanian University of Health Sciences Kaunas Clinics*



**Fig. 3.** Axial T2W MRI scan. Increased retrobulbar perineural signal intensity on both sides of the optic nerves. *Meddream images from the Hospital of the Lithuanian University of Health Sciences Kaunas Clinics*



**Fig. 4.** Axial T1 MRT scan with contrast. Accumulation of contrast agent is observed in the retrobulbar and optic canal region along the nerve sheaths following contrast administration. *Meddream images from the Hospital of the Lithuanian University of Health Sciences Kaunas Clinics*

The blood tests performed at the Neurology Department, i.e., complete blood count, liver enzymes and uremic parameters, were all within the normal limits. An increased C-reactive protein level was associated with a urinary tract infection. The patient tested seropositive for IgG antibodies against *Toxoplasma gondii*, *Borrelia burgdorferi*, *Cytomegalovirus* and *Epstein-Barr virus*. Cerebrospinal fluid analysis showed cytositis ( $15 \times 10^6/L$ ) with a predominance of monomorphonuclear cells, an increase in the total protein concentration to 0.84 g/l, and an increase in the lactate concentration to 3.47 mmol/l. Both serum anti-AQP4-IgG and myelin oligodendrocyte glycoprotein (anti-MOG) were negative. IgG oligoclonal bands were present in the cerebrospinal fluid and serum, indicating a characteristic systemic production of IgG. The IgG index was determined as 0.67. To identify the possible causes of blindness, brain MRI was performed, revealing signs of bilateral optic perineuritis and neuritis; see (Fig. 3) and (Fig. 4). The patient was seen by an ophthalmologist who assessed the patient's condition as bilateral optic neuritis.

The diagnosis of NMOSD was based on the Diagnostic Criteria of the International Panel for NMOSD diagnosis, as updated by the Neuromyelitis Optica Study Group in 2023 (Table 1). The patient was placed on a therapy of intravenous methylprednisolone 1g once a day for five days, and changed to prednisolone PO. In the course of the treatment, no positive response to the steroids therapy was obtained. The patient was transferred to the neurology department of the peripheral hospital for further treatment and care.

## Discussion

*Neuromyelitis Optica Spectrum Disorder* (NMOSD) is a rare inflammatory and demyelinating disease of the *Central Nervous System* (CNS) affecting the optic nerves and spinal cord [1]. The main structural feature of the disease is the presence of IgG antibodies to AQP4, the most abundant water channel located in the astrocyte end-feet. AQP4 plays the central role in the regulation of CNS water homeostasis, preventing glutamate accumulation in the synapses [4]. The onset of NMOSD is most common between 30 and 50 years of age, with up to 30% of cases diagnosed at >60 years of age. Europeans with NMOSD are less likely to have pathological CNS lesions on brain and spinal cord MRI scans [5]. Relapse-remitting clinical course is the most common for NMOSD. The monophasic form is less common. The onset of the disease usually begins with optic neuritis (acute impairment of vision in one or both eyes, painful movement of the eyes, color vision deficiency) and symptoms of transverse myelitis, depending on the level of damage (paresis/plegia of the lower and/or upper limbs, paralysis of the respiratory muscles, visual height intolerance, urination and defecation disorders, painful tonic muscle spasm). Incremental damage to the brainstem leads to progressive hiccups and nausea/vomiting, suggesting damage to the *area postrema*. Furthermore, damage to the thalamus may cause narcolepsy, hypersomnia, and/or hypothermia [6].

The diagnosis of NMOSD was based on the Diagnostic Criteria of the International Panel for NMOSD diagnosis, as updated by the Neuromyelitis Optica Study Group in 2023 (Table 1) [2]. With a positive anti-AQP4 IgG serum test, only one of the main clinical syndromes is sufficient to diagnose the disease. When the anti-AQP4 IgG serum test is negative, or in the case of unavailability for testing, the diagnosis shall be based on at least two clinical syndromes, at least one of which must be optic neuritis, acute myelitis with longitudinally extensive transverse myelitis, or the *areal postrema* syndrome. The spatial spread must be assessed, and the additional MRI criteria based on the clinical syndrome must be met. In our case, anti-AQP4 was not detected by using the *Enzyme-Linked Immunosorbent Assay* (ELISA), which is significantly less accurate compared to cell-based assays. The diagnosis of NMOSD was based on clinical syndromes (optic neuritis, acute myelitis with longitudinally extensive transverse myelitis) and additional MRI findings.

Up to 90% of patients test positive for AQP4-IgG in serum. Anti-MOG is detected in one-third to one-quarter of AQP4-IgG-seronegative patients, and, in this case, it is important to screen younger patients at the onset of the clinical syndromes discussed above [7]. The use of cell-based assays is important so that to avoid false positive and false negative results in immunological tests. Pleocytosis (>50) in the cerebrospinal fluid can be observed from 15% to 35% of AQP4-NMOSD patients [8]. In the clinical case we have presented, cytosis was  $15 \times 10^6/L$  with a predominance of mononuclear cells. However, *Herpes simplex virus* and *Varicella zoster virus* DNA were not detected in the cerebrospinal fluid.

In differentiating from other diseases, testing for possible infectious causes of viral myelitis, as well as evaluating for neurosyphilis and neuroborreliosis is important. Testing to rule out non-infectious inflammatory diseases (multiple sclerosis, neurosarcoidosis, rheumatic diseases, paraneoplastic syndromes) must also be performed. Brain and spinal cord images should be examined for possible vascular changes and volumetric formations. Laboratory tests should be performed to monitor for possible deficiencies of vitamin B12, E, folic acid and Cu [9].

In the case of an acute onset or relapse, a 5–7 day course of intravenous methylprednisolone is usually prescribed. To prevent exacerbations, oral prednisolone is recommended at a dose of 1mg/kg OD, subsequently reducing the dose by 5 mg every 2 weeks until complete cessation. In

the absence of a sufficient response to the intravenous glucocorticosteroid therapy, therapeutic apheresis should be considered. In the case of sero-positive disease, a course-modifying therapy is essential. Presently, four drugs have been approved for treatment: targeting the complement system anti-C5 (eculizumab and ravalizumab), anti-CD19 (inebilizumab), or anti-IL-6 (satralizumab) [10,11].

**Table 1.** The 2015 International Panel for NMOSD Diagnostic Criteria for Adult Patients

---

**Diagnostic criteria for NMOSD with AQP4-IgG**

1. At least 1 core clinical characteristic.
  2. Positive test for AQP4-IgG using the best available detection method (cell-based assay strongly recommended);
  3. Exclusion of alternative diagnoses.
- 

**Diagnostic criteria for NMOSD without AQP4-IgG or NMOSD with unknown AQP4-IgG status**

1. At least 2 core clinical characteristics occurring as a result of one or more clinical attacks and meeting all of the following requirements:
    - a. At least 1 core clinical characteristic must be optic neuritis, acute myelitis with LETM, or area postrema syndrome;
    - b. Dissemination in space (2 or more different core clinical characteristics);
    - c. Fulfillment of additional MRI requirements, as applicable.
  2. Negative tests for AQP4-IgG using the best available detection method, or testing unavailable;
  3. Exclusion of alternative diagnoses.
- 

**Core clinical characteristics**

1. Optic neuritis;
  2. Acute myelitis;
  3. Area postrema syndrome: episode of otherwise unexplained hiccups or nausea and vomiting;
  4. Acute brainstem syndrome;
  5. Symptomatic narcolepsy or acute diencephalic clinical syndrome with NMOSD-typical diencephalic MRI lesions;
  6. Symptomatic cerebral syndrome with NMOSD-typical brain lesions.
- 

**Additional MRI requirements for NMOSD without AQP4-IgG and NMOSD with unknown AQP4-IgG status**

1. Acute optic neuritis: requires brain MRI showing (a) normal findings or only nonspecific white matter lesions, OR (b) optic nerve MRI with T2-hyperintense lesion or T1-weighted gadolinium-enhancing lesion extending over >1/2 optic nerve length or involving optic chiasm;
  2. Acute myelitis: requires associated intramedullary MRI lesion extending over  $\geq 3$  contiguous segments (LETM) OR  $\geq 3$  contiguous segments of focal spinal cord atrophy in patients with a history compatible with acute myelitis;
  3. Area postrema syndrome: requires associated dorsal medulla/area postrema lesions;
  4. Acute brainstem syndrome: requires associated periependymal brainstem lesions.
- 

## Conclusion

The clinical case reported in this paper demonstrates the importance of assessing clinical symptoms, brain and spinal cord images in the diagnosis of NMOSD in patients who have tested negative for serum AQP4 antibodies. To diagnose the disease based on the established criteria, the use of a cell-based assay is essential to detect antibodies as accurately as possible in order to initiate a disease-modifying therapy.

## References

1. VasWu Y, Zhong L, Geng J. Neuromyelitis optica spectrum disorder: Pathogenesis, treatment, and experimental models. *Mult Scler Relat Disord* 2019; 27: 412–8.
2. Wingerchuk DM, Banwell B, Bennett JL, et al. International Panel for NMO Diagnosis. International consensus diagnostic criteria for neuromyelitis optica spectrum disorders. *Neurology* 2015 Jul 14; 85(2): 177–89.
3. Jarius S, Aktas O, et al. Neuromyelitis Optica Study Group (NEMOS). Update on the diagnosis and treatment of neuromyelitis optica spectrum disorders (NMOSD) – revised recommendations of the Neuromyelitis Optica Study Group (NEMOS). Part I: Diagnosis and differential diagnosis. *J Neurol* 2023 Jul; 270(7): 3341–3368.
4. Nagelhus EA, Ottersen OP. Physiological roles of aquaporin-4 in brain. *Physiol Rev* 2013 Oct; 93(4): 1543–62.
5. Sechi E, Cacciaguerra L, et al. Myelin Oligodendrocyte Glycoprotein Antibody-Associated Disease (MOG-AD): A review of clinical and MRI features, diagnosis, and management. *Front Neurol* 2022 Jun 17; 13: 885218.
6. Bukhari W, Clarke L, et al. The clinical profile of NMOSD in Australia and New Zealand. *J Neurol* 2020 May; 267(5): 1431–1443.
7. Waters PJ, Komorowski L, Woodhall M. A multicenter comparison of MOG-IgG cell-based assays. *Neurology* 2019; 92(11): e1250–e1255.
8. Jarius S, Paul F, Franciotta D. Cerebrospinal fluid findings in aquaporin-4 antibody positive neuromyelitis optica: Results from 211 lumbar punctures. *J Neurol Sci* 2011; 306(1–2): 82–90.
9. Kim SM, Kim SJ, et al. Differential diagnosis of neuromyelitis optica spectrum disorders. *Ther Adv Neurol Disord* 2017 Jul; 10(7): 265–289.
10. Chen JJ, Flanagan EP, Pittock SJ, et al. Visual outcomes following plasma exchange for optic neuritis: An international multicenter retrospective analysis of 395 optic neuritis attacks. *Am J Ophthalmol* 2023; 252: 213–224.
11. Rommer P, Zettl UK. Treatment Options in Multiple Sclerosis and Neuromyelitis Optica Spectrum Disorders. *Curr Pharm Des* 2022; 28(6): 428–436.